

PennHIP Report

Referring Veterinarian: Dr Jeffrey Brubaker
 Email: jbrubaker@staytonveterinary.com

Clinic Name: Stayton Veterinary Hospital
 Clinic Address: 1308 North First Ave
 Stayton, OR 97383
 Phone: (503) 769-7387
 Fax: (503) 769-9832

Patient Information

Client: Garfias, Mike & Sydney
 Patient Name: Poe
 Reg. Name: The Raven of Moro "Poe"
 PennHIP Num: 177851
 Species: Canine
 Date of Birth: 27 Jul 2021
 Sex: Female
 Date of Study: 18 Aug 2022
 Date of Report: 19 Aug 2022

Tattoo Num:
 Patient ID: 56675
 Registration Num:
 Microchip Num: 956000013713216
 Breed: WHITE SWISS SHEPHERD DOG
 Age: 13 months
 Weight: 63 lbs/28.6 kgs
 Date Submitted: 18 Aug 2022

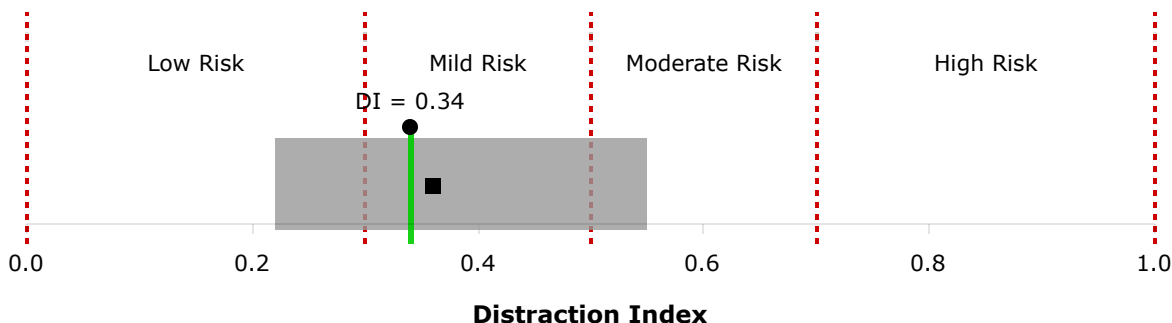
Findings

Distraction Index (DI): Right DI = 0.34, Left DI = 0.30.
 Osteoarthritis (OA): **No radiographic evidence of OA for either hip.**
 Cavitation/Other Findings: No cavitation present.

Interpretation

Distraction Index (DI): The laxity ranking is based on the hip with the greater laxity (larger DI). In this case the DI used is 0.34.
 OA Risk Category: The DI is between 0.31 and 0.49. This patient is at mild risk for hip OA.
 Distraction Index Chart:

WHITE SWISS SHEPHERD DOG



BREED STATISTICS: This interpretation is based on a cross-section of 124 canine patients of the WHITE SWISS SHEPHERD DOG breed in the AIS PennHIP database. The gray strip represents the central 90% range of DIs (0.22 - 0.55) for the breed. The breed average DI is 0.36 (solid square). The patient DI is the solid circle (0.34).

SUMMARY: The degree of laxity (DI = 0.34) falls within the central 90% range of DIs for the breed. This amount of hip laxity places the hip at a mild risk to develop hip OA. **No radiographic evidence of OA for either hip.**